


PATIENT PRESENTING CLINICAL SIGNS

Tully Wright History: Chronic diarrhea, hyporexia, weight loss. Treated with intestinal and hypoallergenic diet, omeprazole and Cerenia.

SPECIES Physical Examination: N/A.

Canine Urinalysis: N/A.

BREED CBC: N/A.

West Highland White terrier Serum Biochemistry: N/A.

terrier Radiographic Findings: N/A.

SEX

MN

Age

8 years

WEIGHT

6.5 kg

INTERPRETED BY

Remo Lobetti, BVSc,
MMedVet (Med), PhD,
Dipl. ECVIM

ULTRASONOGRAPHIC EXAMINATION OF THE ABDOMEN
Urinary System

Full urinary bladder with a normal thickness and appearance of the wall. Normal anechoic urine with no sediment evident. Two uroliths (0.5 cm, 0.6 cm) present.

Normal trigone area, proximal urethra, and iliac blood vessels.

Normal iliac lymph nodes (0.9 cm, 1.2 cm). Ureters not visualized.

Normal renal size (left 4.1 cm right 3.9 cm), echogenic appearance, cortico-medullary differentiation, pelvis, and capsule.

Reproductive System

N/A.

Adrenal Glands

Normal shape, echogenic appearance, and position but small in size. Left 0.24/0.26 cm, right 0.35/0.31 cm.

Spleen

Normal size and echogenic appearance. Smooth homogenous parenchyma, regular curvilinear capsule, and normal vasculature. No evidence of inflammatory, neoplastic, infarction, or infiltrative changes noted.

Liver

Normal size, echogenic appearance, portal markings, and regular curvilinear capsule. No nodules or masses evident. Full gall bladder containing normal anechoic bile. Normal thickness and appearance of the gall bladder wall. Normal bile duct.

IMAGING PERFORMED BY

Dr Stan Gira

HOSPITAL NAME

Resolution Veterinary
Ultrasound

REFERRING VET

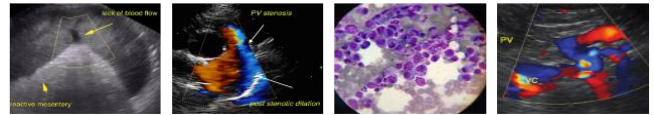
Dr Stan Gira

INVOICE

303334

DATE

8/25/22


PATIENT

Tully Wright

SPECIES

Canine

BREED

 West Highland White
 terrier

SEX

MN

Age

8 years

WEIGHT

6.5 kg

INTERPRETED BY

 Remo Lobetti, BVSc,
 MMedVet (Med), PhD,
 Dipl. ECVIM

**IMAGING PERFORMED
 BY**

Dr Stan Gira

HOSPITAL NAME

 Resolution Veterinary
 Ultrasound

REFERRING VET

Dr Stan Gira

INVOICE

303334

DATE

8/25/22

Gastrointestinal

Normal appearance of the small intestine, ileo-cecal junction, and colon with no loss of layering, normal wall thickness and peristaltic activity, and no distension of the lumen. Thickening of the gastric wall (0.9 cm) and pylorus (1.6 cm) with some loss of layering. Moderate amount of ingesta within the stomach. Thickening of the duodenum (0.6 cm) with a prominent hypoechoic appearance of the submucosal layer but with no loss of layering or distension of the lumen.

Pancreas

Normal size (right 1.1 cm, left 0.9 cm) and echogenic appearance. Regular capsule. Normal echogenic appearance of the mesentery and fat surrounding the pancreas.

Free Abdomen

Normal mesenteric lymph nodes (0.7 cm).

No ascites.

Normal size of the aorta, caudal vena cava, and portal vein.

ULTRASONOGRAPHIC FINDINGS

Primary Findings:

- Gastropathy
- Duodenopathy.
- Small adrenal glands.

Secondary Findings:

- Uroliths.

INTERPRETATION OF THE FINDINGS & FURTHER RECOMMENDATIONS

Etiologies for the stomach would be chronic gastritis, *Helicobacter* gastritis, helminths, ulcerative disease, granulomatous gastritis, inflammatory bowel disease, and neoplasia.

Etiologies for the duodenum would be inflammatory bowel disease, dietary hypersensitivity, and parasitic enteritis.

Although the small adrenal glands may be an incidental finding, Addison's disease needs to be considered.

Further assessment would be urine and fecal analyses, basal cortisol assay, and gastroscopy with biopsies.

Specific therapy would be dependent on an etiological diagnosis.



PATIENT

Tully Wright

SPECIES

Canine

BREED

West Highland White
terrier

SEX

MN

Age

8 years

WEIGHT

6.5 kg

INTERPRETED BY

Remo Lobetti, BVSc,
MMedVet (Med), PhD,
Dipl. ECVIM

IMAGING PERFORMED BY

Dr Stan Gira

HOSPITAL NAME

Resolution Veterinary
Ultrasound

REFERRING VET

Dr Stan Gira

INVOICE

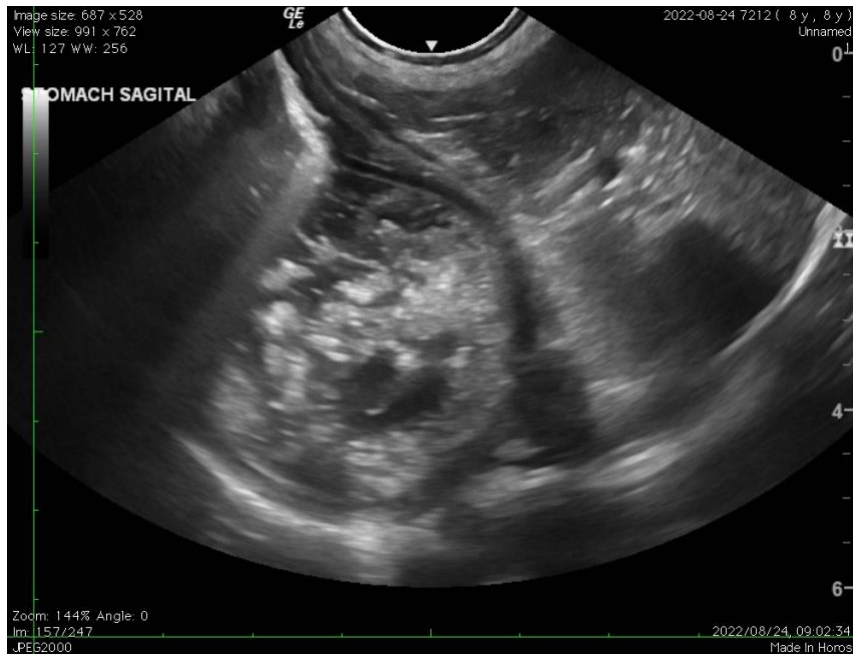
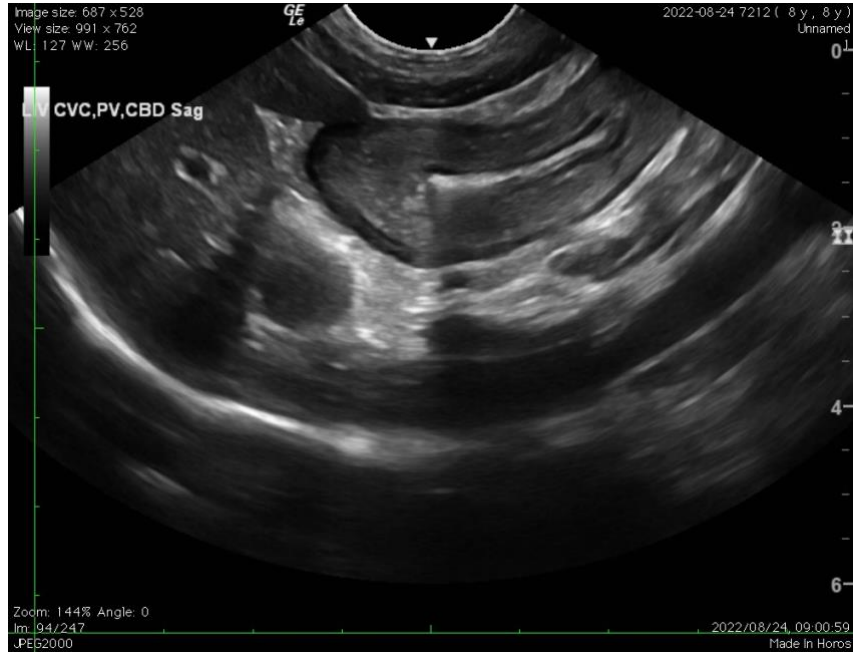303334

DATE

8/25/22

IMAGES

Stomach





PATIENT

Duodenum

Tully Wright

SPECIES

Canine

BREED

West Highland White
 terrier

SEX

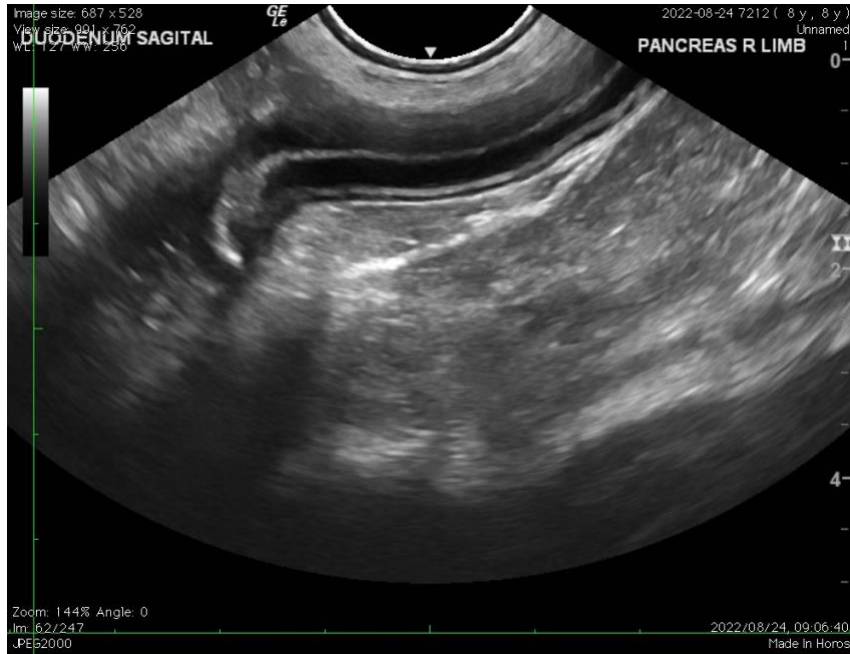
MN

Age

8 years

WEIGHT

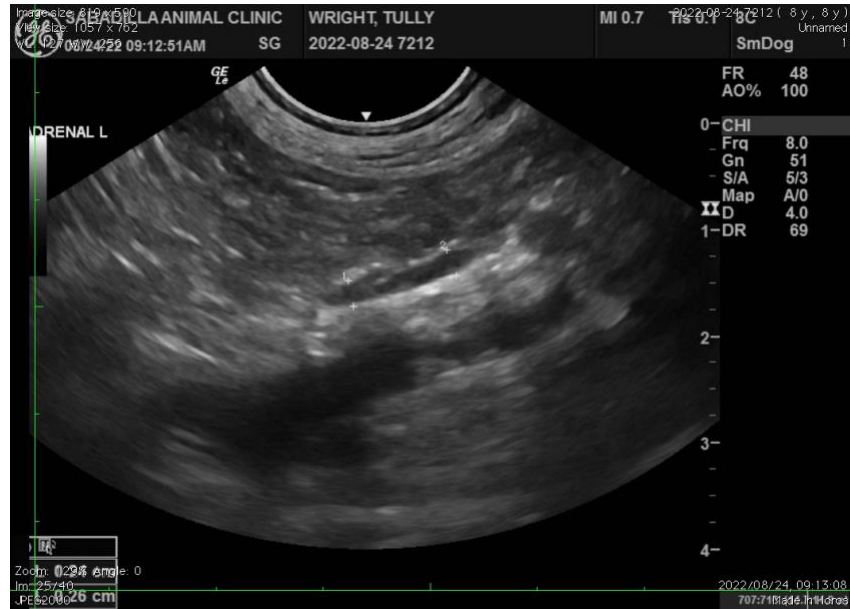6.5 kg



INTERPRETED BY

Right adrenal

Remo Lobetti, BVSc,
 MMedVet (Med), PhD,
 Dipl. ECVIM



IMAGING PERFORMED BY

Dr Stan Gira

HOSPITAL NAME

Resolution Veterinary
 Ultrasound

REFERRING VET

Dr Stan Gira

INVOICE

303334

DATE

8/25/22



PATIENT

Urinary bladder

Tully Wright

SPECIES

Canine

BREED

West Highland White
terrier

SEX

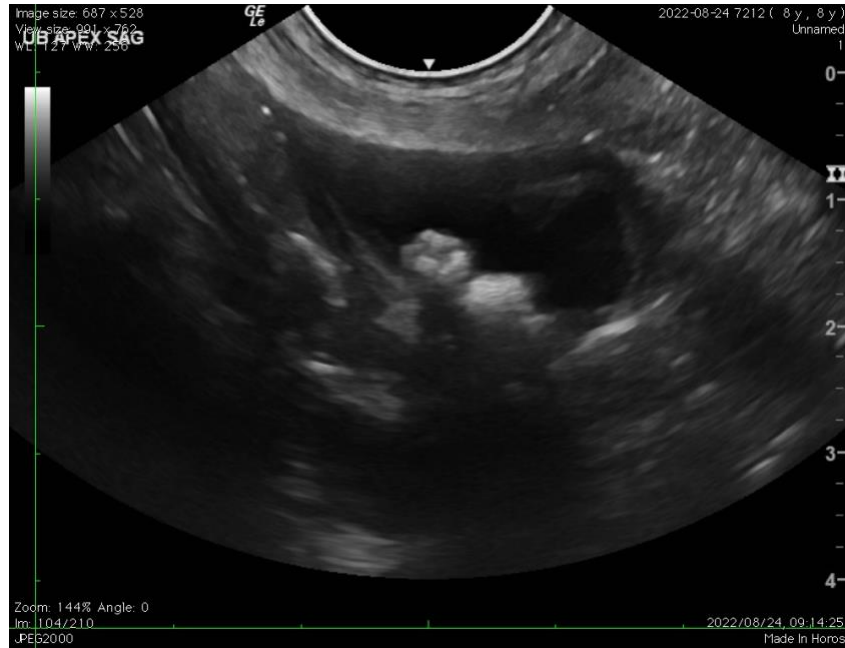
MN

Age

8 years

WEIGHT

6.5 kg



INTERPRETED BY

Remo Lobetti, BVSc,
MMedVet (Med), PhD,
Dipl. ECVIM

The information and recommendations provided are based on the images presented by the referring veterinarian. No evaluation can be communicated regarding pathology that was not visible in the image/video clips provided.

IMAGING PERFORMED BY

Dr Stan Gira

Thank you for this referral. If the clinical or image interpretation does not parallel your findings or if I can be of any further assistance, please contact me.

Remo Lobetti, BVSc, MMedVet (Med), PhD, Dipl. ECVIM (Internal Medicine)
robetti@mweb.co.za

HOSPITAL NAME

Resolution Veterinary
Ultrasound

REFERRING VET

Dr Stan Gira

INVOICE

303334

DATE

8/25/22